

PATIENT

Punim Sobol

SPECIES

Canine

BREED

Shih-Poo

SEX

MN

AGE

13 years

WEIGHT

13.5 #

INTERPRETED BY

Remo Lobetti, BVSc,
MMedVet (Med),
PhD, Dipl. ECVIM

**IMAGING
PERFORMED BY**

Lara Wiseman, DVM

HOSPITAL NAME

Boca Midtowne
Animal Hospital

REFERRING VET

INVOICE

302580

DATE

10/1/21

PRESENTING CLINICAL SIGNS

History: Oral malignant mass – ultrasound screening for metastatic disease.

Physical Examination: N/A.

Urinalysis: N/A.

CBC: N/A.

Serum Biochemistry: N/A.

Radiographic Findings: N/A.

ULTRASONOGRAPHIC EXAMINATION OF THE ABDOMEN

Urinary System

Full urinary bladder with a normal thickness and appearance of the wall. Normal anechoic urine with no sediment or uroliths evident.

Normal trigone area, proximal urethra (0.3 cm) and iliac blood vessels.

Normal iliac lymph nodes. Ureters not visualized.

Normal renal size (left kidney 3.9 cm, right 3.6 cm) with increased echogenic appearance, some loss of cortico-medullary differentiation, and normal capsule and pelvis.

Reproductive System

Small hypoechogenic prostate (0.71 cm).

Adrenal Glands

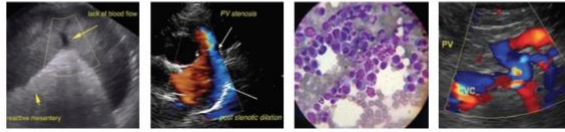
Normal shape, echogenic appearance, size, and position. Left 0.5 cm, right 0.52 cm.

Spleen

Normal size (1.2 cm) and echogenic appearance. Smooth homogenous parenchyma, smooth curvi-linear capsule, and normal vasculature. No evidence of inflammatory, neoplastic, infarction, or infiltrative changes noted.

Liver

Normal size, echogenic appearance, and portal markings. No nodules or masses evident. Full gall bladder containing normal anechoic bile. Normal appearance and thickness of the gall bladder wall. Normal bile duct (0.14 cm).



PATIENT

Punim Sobol

SPECIES

Canine

BREED

Shih-Poo

SEX

MN

AGE

13 years

WEIGHT

13.5 #

INTERPRETED BY

Remo Lobetti, BVSc,
MMedVet (Med),
PhD, Dipl. ECVIM

**IMAGING
PERFORMED BY**

Lara Wiseman, DVM

HOSPITAL NAME

Boca Midtowne
Animal Hospital

REFERRING VET

INVOICE

302580

DATE

10/1/21

Gastrointestinal

Normal appearance of the gastro-esophageal junction, stomach, pylorus, duodenum, small intestine, ileo-cecal junction, and colon with no loss of layering and normal wall thickness (stomach 0.25 cm, duodenum 0.42 cm, jejunum 0.24 cm) and peristalsis, and no distension of the lumen.

Pancreas

Normal size (right 1 cm) and echogenic appearance. Regular capsule. Normal echogenic appearance of the mesentery and fat surrounding the pancreas.

Free Abdomen

No mesenteric lymphadenomegaly.
No ascites.

ULTRASONOGRAPHIC FINDINGS

Primary findings:

- Age-related renal changes vs renal disease.

Secondary findings:

- None.

INTERPRETATION OF THE FINDINGS & FURTHER RECOMMENDATIONS

On this ultrasound there is no obvious evidence of metastatic disease.

Although the appearance of the kidneys may merely be age-related, chronic kidney disease needs to be considered and differentiated by means of urinalysis and renal function testing (urea, creatinine, SDMA) .



PATIENT

Punim Sobol

SPECIES

Canine

BREED

Shih-Poo

SEX

MN

AGE

13 years

WEIGHT

13.5 #

INTERPRETED BY

Remo Lobetti, BVSc,
MMedVet (Med),
PhD, Dipl. ECVIM

IMAGING PERFORMED BY

Lara Wiseman, DVM

HOSPITAL NAME

Boca Midtowne
Animal Hospital

REFERRING VET

INVOICE

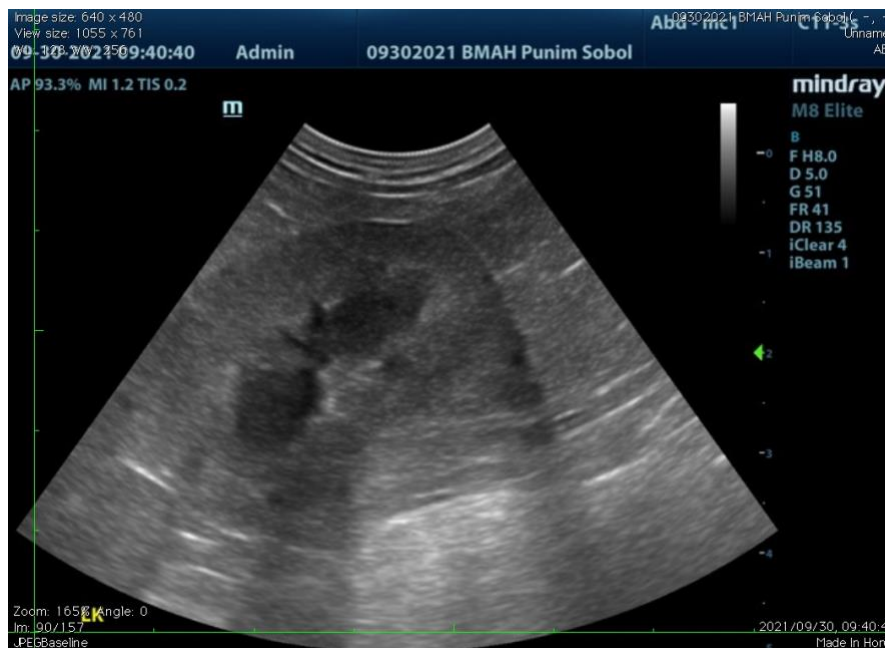302580

DATE

10/1/21

IMAGES

Left kidney



The information and recommendations provided are based on the images presented by the referring veterinarian. No evaluation can be communicated regarding pathology that was not visible in the image/video clips provided.

Thank you for this referral. If the clinical or image interpretation does not parallel your findings or if I can be of any further assistance please contact me.

Remo Lobetti, BVSc, MMedVet (Med), PhD, Dipl. ECVIM (Internal Medicine)
rlobetti@mweb.co.za